

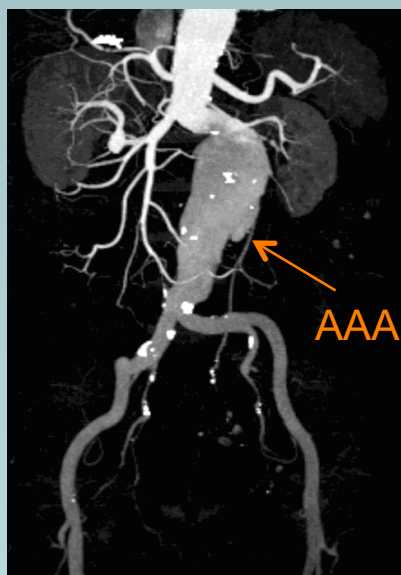
Kenneth Herskowitz, MD
Chief of Cardiovascular
Surgery
1625 South East 3rd Ave.
Suite 300
Fort Lauderdale, FL 33316
(954) 355-4665
www.kherskowitzmd.com



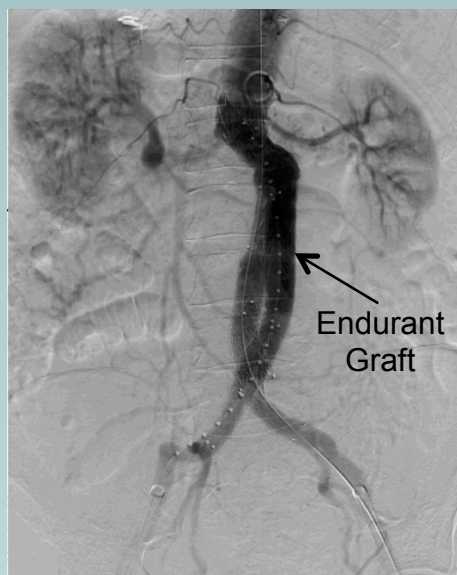
Michael Gordon, MD/PhD
North Broward Radiologists
1801 S. Perimeter Road
Suite 180
Fort Lauderdale, FL 33309
(954) 355-5516

79 year-old male with a history of hypertension and prior coronary bypass surgery who was followed for an enlarging infrarenal abdominal aortic aneurysm (AAA).

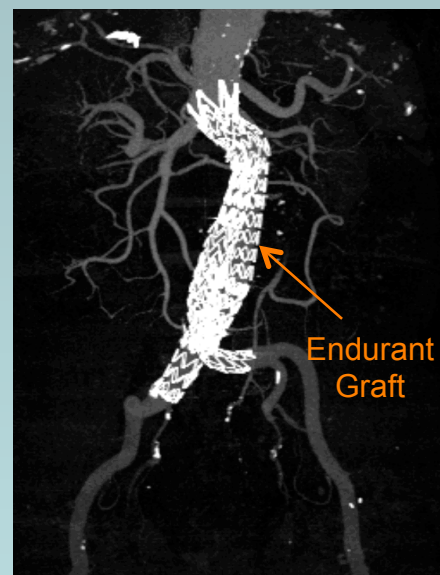
His aneurysm enlarged from 4 cm in 2007 to 4.5 cm in 2009. By 2011 it was 6.4 cm and had proximal neck angulation of 90 degrees. Despite this, it was successfully treated with an Endurant stent graft placed within 1 mm of the renal arteries.



Pre-operative CT



Intra-operative Angiogram



Post-operative CT

“The new technology that the Endurant II Stent Graft offers provides the physician the best chance to treat complicated and difficult AAA anatomy,” Dr. Herskowitz.

Broward Health has recently opened a new state of the art Hybrid Operating Suite to treat complex Abdominal and Thoracic aneurysms.